


# DIFFICULT SURGERY GIANT RETINAL TEAR



TIMELY INTERVENTION IN RETINAL  
EMERGENCIES CAN SAVE SIGHT!

## PATIENT DETAILS

- Age: 46 years
- Gender: Male
- Pseudophakic patient with pathological myopia and history of trauma.

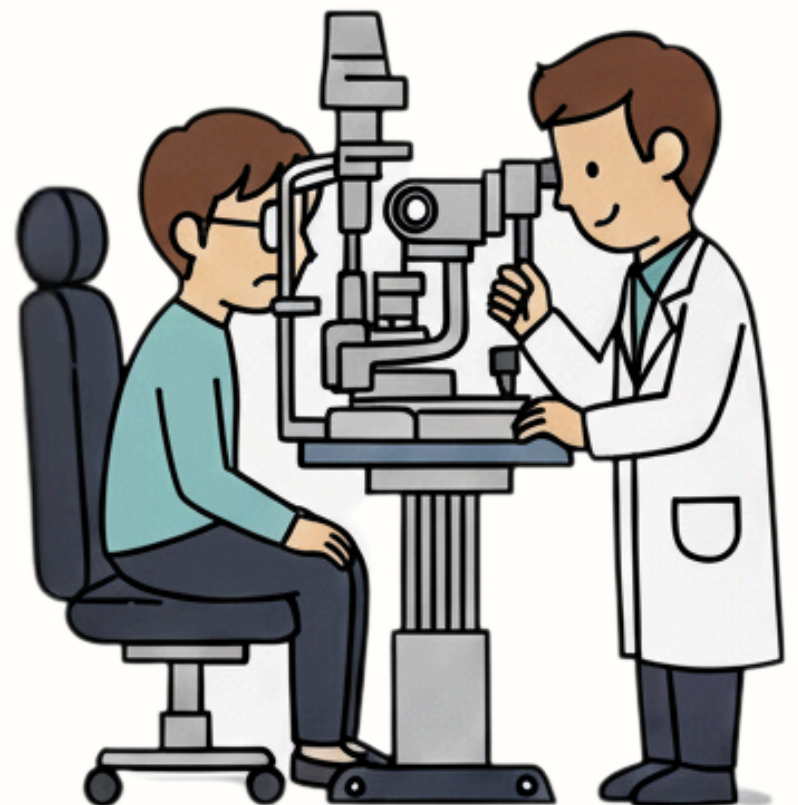

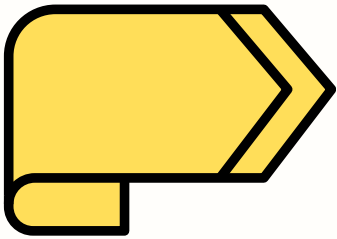
## CHIEF COMPLAINT

- Sudden, severe vision loss.

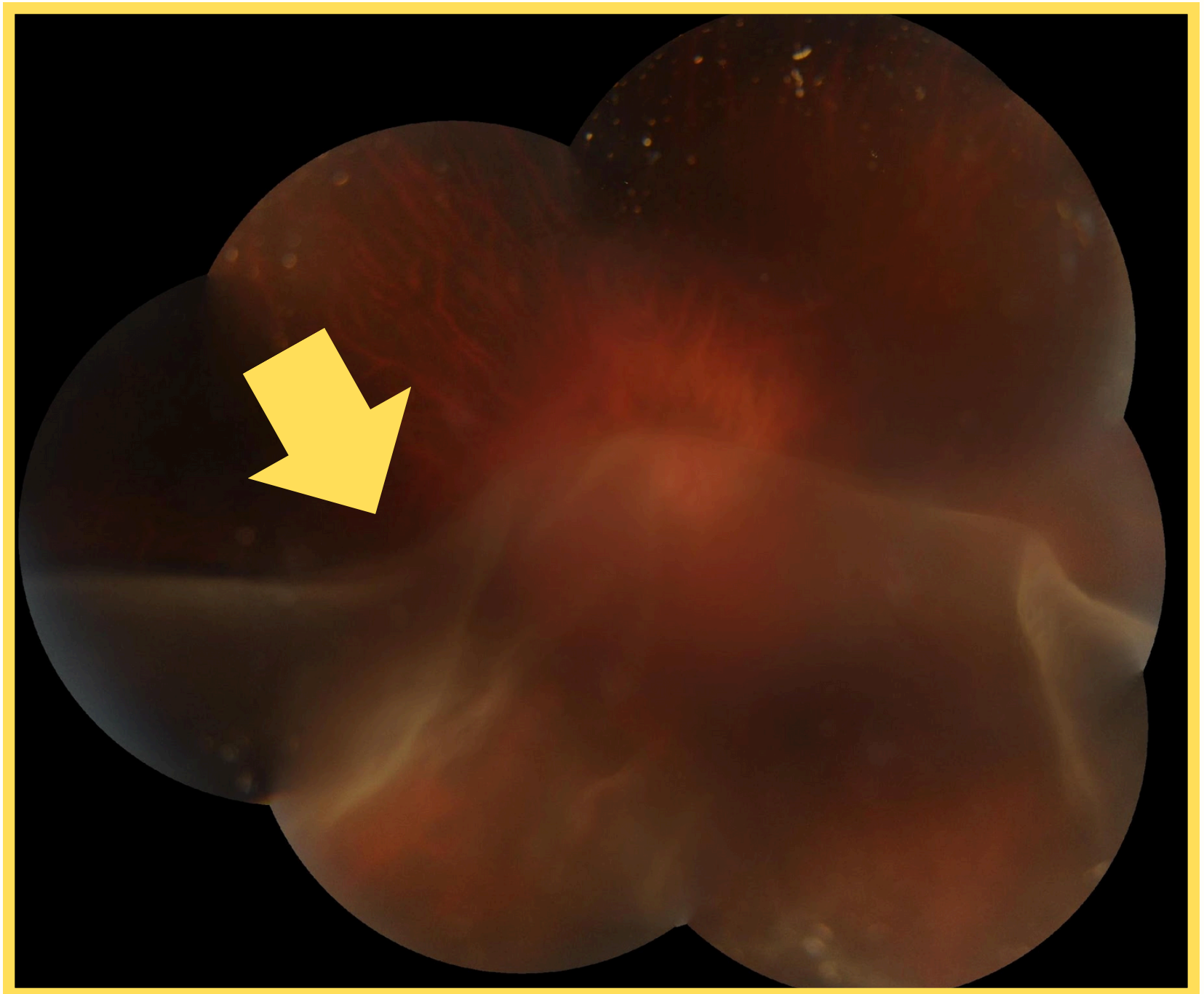
## CLINICAL EXAMINATION

- Giant Retinal Tear
- Total Retinal Detachment
- Retina folded upon itself like a tortilla





**There was a total Retinal Detachment with the retina folded upon itself like a tortilla !**




## TREATMENT

- Complex retinal surgery with silicone oil tamponade.

## OUTCOME

- Retina successfully reattached
- Post-operative vision: 6/18
- Happy patient with restored functional vision!



## SYMPTOMS TO WATCH FOR

- **Flashes of light:** These may be sudden and appear like lightning streaks.
- **New floaters:** A sudden increase in small dark specks, lines, or cobwebs that drift through your vision.
- **A dark shadow or "curtain":** This shadow may appear in your peripheral (side) vision and spread, or it can cover a part of your central vision.
- **Sudden blurred vision:** This can happen if the central area of the retina, the macula, becomes detached.

Book your appointment  
today!

